Protective effect of calcium folinate against methotrexate-induced endosalpinx damage in rats

The aim of this study was to evaluate the protective effect of calcium folinate (CF) applied in 10% of the methotrexate (MTX) dosage against morphologic and steroid-receptor damage induced by MTX in rat endosalpinx. The result indicated that endosalpingitis, the ultrastructural damage of endosalpinx, and a change in estrogen and P receptor expression induced by low- and high-dose MTX in endosalpinx can be reversed completely and partly (B1, B2) by combined treatment with CF, suggesting that CF combined with MTX protects against the side effects induced by MTX. (Fertil Steril® 2011;95:1526–30. ©2011 by American Society for Reproductive Medicine.)

Key Words: Methotrexate, calcium folinate, endosalpinx, morphology, immunohistochemistry, estrogen receptor, progesterone receptor

Methotrexate (MTX) is a classical folate antagonist that has been used in the treatment of ectopic pregnancy (EP) for many years (1–16). Patients with EP can be successfully treated with MTX in various protocols and approaches (1–3, 5–10). However, laboratory evidence suggests that MTX can induce toxicity in the endosalpinx (17–19). Although the regimen of MTX plus folinic acid is known to be safe and effective for EP in the clinic (20, 21), subsequent tubal patency and reproductive function are not well understood (21). A recent study showed that folic acid at a fixed dose of 0.1 mg/kg can alleviate ultrastructural derangements induced by MTX to some extent in the fallopian tube of the rat (22). However, it would be more convincing if a dynamic dose of folic acid were applied according to the increasing dose of MTX in a group experiment.

The present study evaluated the protective effects of CF applied in 10% of the MTX dose against MTX-induced tubal alterations by routine histology, ultrastructural examination, and immunohistochemistry for ER and PR simultaneously. In addition, we aimed to provide significant laboratory evidence supporting the use of CF combined with MTX in the treatment of EP.

Eighty female Sprague-Dawley rats (weighing 180–200 g) in the estrus stage obtained from our institute under specific pathogen-free conditions were randomly divided equally into groups A0-3 and B0-3. A0 and B0 received intraperitoneal (IP) injection of physiologic saline and 0.5 mg/kg body weight CF, respectively, as a control. A1-3 and B1-3 received MTX (1, 2, 5 mg/kg IP) accordingly, plus CF (0.1, 0.2, 0.5 mg/kg IP) for B1-3 24 hours after MTX injection. The range of MTX and CF (AnHui Pharmaceutical Factory, Hefei City, China) was chosen according to the literature (1, 2, 8–19, 22). However, we designed a dynamic dose of CF applied in 10% of the MTX dose to evaluate its true capability to protect susceptible endosalpinx tissues.

The tubal ampullary region is the most common site for an ectopic pregnancy (23), and it shows stable expression of steroid receptors during the estrous cycles (24). Therefore, 10 days later, tissue samples of the ampullary portion were removed from all rats, which were killed by cervical dislocation, and prepared for hematoxylin and eosin staining (25), transmission electron microscopy (TEM) (26) and immunohistochemical analysis (27) by a pathologist blinded to the experiment design. Histopathology was assessed semiquantitatively for the presence of inflammatory cells (lymphocytes and plasma cells) (28). ER polyclonal antibody (Wuhan Boster Biological Technology, Wuhan City, China) and PR monoclonal antibody (Novocastra Laboratories, Newcastle upon Tyne, United Kingdom) immunostaining were also analyzed semiquantitatively by Image Quant software (Molecular Dynamics, Sunnyvale, CA). Data were expressed as mean ± SD and analyzed by ANOVA or Student's *t* test, followed by Dunnett's test for comparison between control and test groups; $P < 0.05$ was

Xiao-Jun Yang, Ph.D[a]
Yan-Ping Chen, M.D.[a]
Han-Chu Wang, M.D.[a]
Jing Zhao, M.D.[b]
Fei-Yun Zheng, M.D.[a]
[a] *Department of Obstetrics and Gynecology, The First Affiliated Hospital of Wenzhou Medical College, Wenzhou, Zhejiang, People's Republic of China*
[b] *Department of Pathology, The First Affiliated Hospital of WenZhou Medical College, Wenzhou, Zhejiang, People's Republic of China*

Received January 24, 2010; revised July 16, 2010; accepted August 13, 2010; published online September 24, 2010.
X-J.Y. has nothing to disclose. Y-P.C. has nothing to disclose. H-C.W. has nothing to disclose. J.Z. has nothing to disclose. F-Y.Z. has nothing to disclose.
X-J.Y. and Y-P.C. contributed equally to this work.
Supported by the Medical Health Science Research Foundation of Zhejiang Province in China (grant no. 2007B143), and the Distinguished Ph.D. Scholars of the First Affiliated Hospital of Wenzhou Medical College (grant no. 2007SB09).
Reprint requests: Fei-Yun Zheng, M.D., Department of Obstetrics and Gynecology, The First Affiliated Hospital of Wenzhou Medical College, Wenzhou, Zhejiang Province 325000, People's Republic of China (E-mail: k-ras@sohu.com).

0015-0282/$36.00
doi:10.1016/j.fertnstert.2010.08.028

FIGURE 1

Semiquantitative analysis of ER and PR immunostaining intensity in the MTX group (A0-A3, *solid bars*) and the MTX + CF group (B0-B3, *open bars*). The means and SDs were calculated from 12 regions per section on three representative sections from each rat. Within the MTX group (*d* and *e*) or the MTX + CF group (*D*), the bars that do not share a letter are significantly different. Asterisks indicate a significant difference between MTX and MTX + CF (Student's *t* test; $^{*}P = 0.002$; $^{**}P = 0.000$). When compared within MTX or MTX + CF, one-way ANOVA showed significant differences within group A (both for ER and PR expression; $P = 0.000$). An additional Dunnett's test showed significant differences between control and test values (for ER expression: A2 vs. A0, $P = 0.001$; A3 vs. A0, $P = 0.000$; for PR expression: A3 vs. A0, $P = 0.000$).

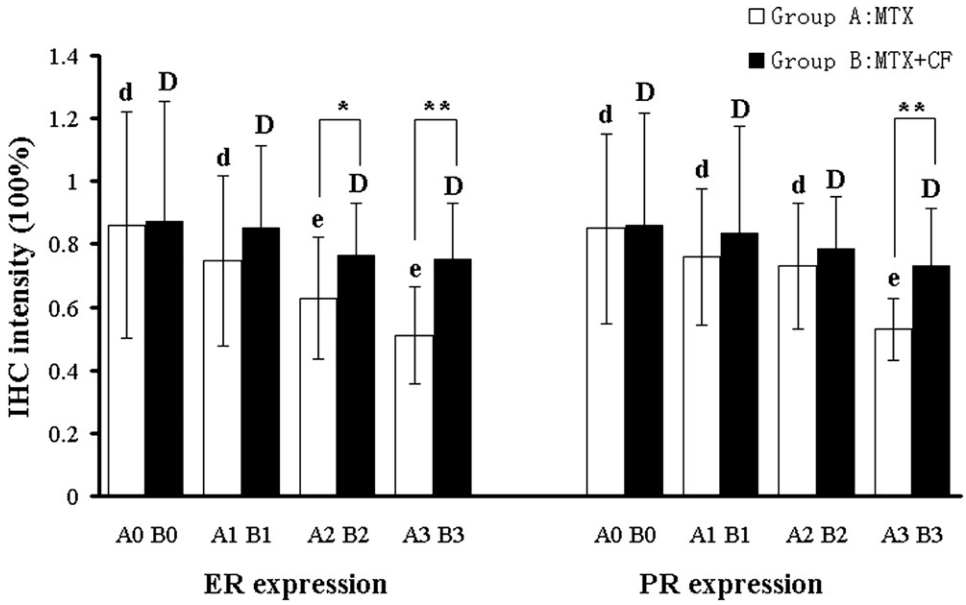

Yang. CF alleviates MTX toxicity in endosalpinx. Fertil Steril 2011.

considered statistically significant. The study design and methodology were approved by the Institutional Review Board of Wenzhou Medial College.

Histopathologic observation showed that inflammatory cell infiltration in the endosalpinx was more intensive in the high-dose MTX group. However, endosalpingitis seems to be prevented completely by CF in B1, B2, and B3 (data not shown).

Steroid receptor expression significantly decreased with increasing doses of MTX, but such damage was reversible and could be rescued by CF to near normal levels completely in all dosage groups (Fig. 1).

TEM analysis of cellular ultrastructures showed that MTX exposure induced mitochondrial swelling and vacuolization, and loss of extracellular microvilli in ciliated cells. Mitochondrial vacuolization and deformation, nuclei pyknosis, and compensatory increased secretory granules appeared in nonciliated cells. However, ultrastructural damage induced by low-dose MTX in the endosalpinx can be reversed completely (B1, B2), whereas the protective effect of CF may be limited in a high dose MTX (B3), in which multiple irreversible ultrastructural alterations occur (Figs. 2–4). Meanwhile, morphologic structures remain normal in control A0 and B0.

Folates are essential for embryonic development and growth (29). Antifolate substances, represented by MTX, continue to occupy a unique and important niche among modern pharmacopoeia for patients with EP (1–16). MTX can inhibit normal trophoblasts and decrease cytotrophoblast differentiation and proliferation (4, 30), and it can be used to treat EP effectively (1–3, 5–10). However, as a folate antagonist, systemic toxicity limits the therapeutic value of MTX, such as toxicity in hematologic tissue (31, 32), gastrointestinal mucosa cells (33, 34), and ovarian tissue (35, 36). Recently, Bayram et al. (17) and Cetin et al. (18) reported that

FIGURE 2

Compensatory increase of secretory granules at the top of nonciliated cells (TEM, original magnification, ×15,000).

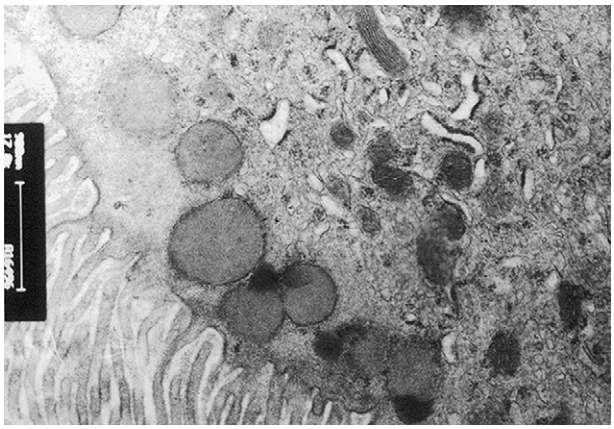

Yang. CF alleviates MTX toxicity in endosalpinx. Fertil Steril 2011.

FIGURE 3

Cell nuclei chromatin pyknosis with endoplasmic reticulum distention and vacuolization (TEM, original magnification, ×3,700).

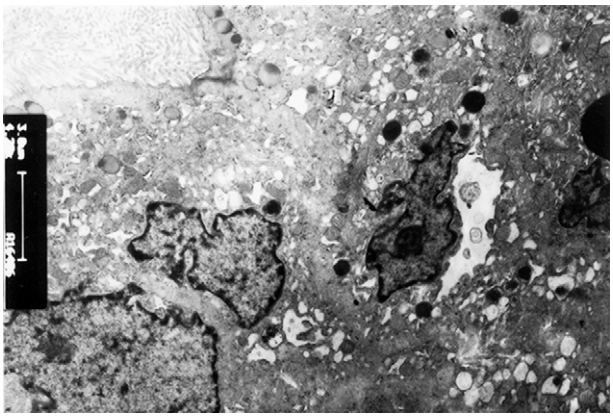

Yang. CF alleviates MTX toxicity in endosalpinx. Fertil Steril 2011.

FIGURE 4

Loss of cilia is still apparent (TEM, original magnification, ×8,900).

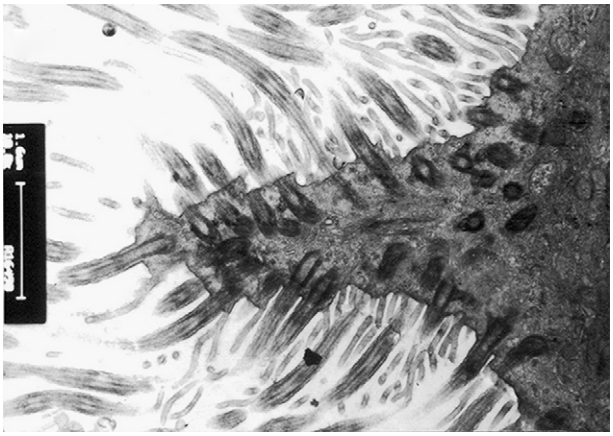

Yang. CF alleviates MTX toxicity in endosalpinx. Fertil Steril 2011.

MTX exposure can cause ultrastructural alterations in the endosalpinx. Furthermore, we reported preliminary results that MTX can cause long-term, irreversible steroid receptor damage in the rat endosalpinx, putting the tube at high risk for subsequent EP or infertility (19).

In 1964, literature showed that folic acid can help alleviate the systemic toxicity of MTX, and that the regimen of MTX plus folinic acid is safe and effective in patients with EP (20, 21). However, subsequent tubal patency and reproductive function are yet to be ascertained (21). More recently, Bayram et al. reported that folic acid (0.1 mg/kg) can rescue derangement of the tubo-ovarian ultrastructural architecture induced by MTX to some extent in the rat endosalpinx (22). Generally, the dose of folic acid for normal rescue therapy must be increased significantly in patients with elevated MTX concentrations (37). However, the total amount of folic acid usually cannot exceed a recommended dose of 10% of MTX (38, 39). Therefore, we designed a dynamic dose of CF applied in 10% of the MTX dose and obtained compelling evidence for a "rescue effect" of CF by protecting susceptible cells lining in the endosalpinx from MTX-induced morphologic and steroid receptor damage simultaneously. Furthermore, we demonstrated an increase in dose tolerance of MTX resulting from the combination with CF in 10% of the MTX dose.

A normal endosalpinx mainly consists of ciliated cells distributed on the surface of the epithelium with abundant microvilli and uniform height and movement. Nonciliated cells are situated sporadically and have a secretory function (17, 40, 41). Generally, the tubal microenvironment, which is essential for a number of reproductive processes, depends on the integrity of the epithelium (41). Interactions between sperm and the endosalpinx are highly important in reproductive processes (42), including improving sperm motility characteristics, inducing capacitation, and increasing sperm fertilizing ability (43–45). In addition, the peristaltic pump of fallopian tubes is under the endocrine control of the ovary. Estrogen contributes to muscle contraction toward fimbriae of the oviduct and induces isthmus shrinkage, whereas P acts against estrogen-induced contractions (19). A local, stable microenvironment is essential for the coordinated movement of ciliated cells, muscle layers, and other reproductive processes. Failure of this mechanism is responsible for tubal implantation or infertility (46–49).

In this study, MTX-induced endosalpingitis and ER and PR damage was consistent with our preliminary report (19). Furthermore, we demonstrated the first laboratory evidence that such damage was a transient and reversible event, which can be prevented completely by CF applied in 10% of the MTX dose, as observed by light microscopy. Meanwhile, ultrastructural damage also can be reversed completely in a low dose MTX (B1, B2), manifested as an increased dose tolerance of MTX, and exerts little effect on normal fertility.

On the contrary, the observed multiple irreversible ultrastructural alterations induced by high-dose MTX (B3) in the endosalpinx suggests an increased risk of developing dysfunction and mechanical occlusion or blockage of the tube (41). Compensatory increased secretion in nonciliated cells can lead to abnormal fluid secretion and absorption; therefore, it can cause the formation of hydrosalpinx fluid (Fig. 2) (41, 50). Cell nuclei chromatin pyknosis with endoplasmic reticulum distention and vacuolization may be the initiation of fibrosis in the endosalpinx (Fig. 3) (41). Loss of cilia will impair the movement of ciliated cells (Fig. 4), which is essential for the transfer of sperm, oocyte, or embryo, thereby affecting fertilization and pregnancy rates (41–45). In addition, these damaged epithelia may be the source of the release of cytokines, abnormal proteins, and other bioactive substances, including cytokines such as tumor necrosis factor α, which are associated with toxicity to germ cells and less embryo development (41, 50). Consequently, a disturbance in the microenvironment in the endosalpinx will lead to tubal implantation or infertility (17, 23, 40, 41, 46, 48).

To our knowledge, this laboratory study is the first to evaluate the rescue effect of CF against morphologic and steroid receptor (ER, PR) damage induced by MTX in the rat endosalpinx. In addition, this study provides insight into the potential pharmacologic effect

on the regulation of reproductive functions undertaken by the fallopian tube. The results suggest an increase in dose tolerance of MTX resulting from the combination with CF in 10% of the MTX dosage. Nevertheless, MTX can induce oxidative stress on proteins, lipids, and DNA through a wide range of cellular, biochemical, and molecular approaches (29, 51–53). Therefore, further laboratory investigation is needed to expand knowledge of protective mechanisms of folic acid against MTX-induced free radical damage.

REFERENCES

1. Robertson DE, Smith W, Moye MA, Brinsden PR, Hansen JN, Lewis PM, et al. Reduction of ectopic pregnancy by injection under ultrasound control. Lancet 1987;1:974–5.
2. Leeton J, Davison G. Nonsurgical management of unruptured tubal pregnancy with intra-amniotic methotrexate: preliminary report of two cases. Fertil Steril 1988;50:167–9.
3. Pansky M, Bukovsky J, Golan A, Avrech O, Langer R, Weinraub Z, et al. Reproductive outcome after laparoscopic local methotrexate injection for tubal pregnancy. Fertil Steril 1993;60:85–7.
4. Floridon C, Nielsen O, Byrjalsen C, Holund B, Kerndrup G, Thomsen SG, et al. Ectopic pregnancy: histopathology and assessment of cell proliferation with and without methotrexate treatment. Fertil Steril 1996;65:730–8.
5. Mesogitis SA, Daskalakis GJ, Antsaklis AJ, Papantoniou NE, Papageorgiou JS, Michalas SK. Local application of methotrexate for ectopic pregnancy with a percutaneous puncturing technique. Gynecol Obstet Invest 1998;45:154–8.
6. Natofsky JG, Lense J, Mayer JC, Yeko TR. Ultrasound-guided injection of ectopic pregnancy. Clin Obstet Gynecol 1999;42:39–47; quiz 55–6.
7. Sagiv R, Golan A, Arbel-Alon S, Glezerman M. Three conservative approaches to treatment of interstitial pregnancy. J Am Assoc Gynecol Laparosc 2001;8:154–8.
8. Lipscomb GH, Meyer NL, Flynn DE, Peterson M, Ling FW. Oral methotrexate for treatment of ectopic pregnancy. Am J Obstet Gynecol 2002;186:1192–5.
9. Mol BW, Hajenius PJ, Engelsbel S, Ankum WM, Hemrika DJ, Van der Veen F, et al. Treatment of tubal pregnancy in the Netherlands: an economic comparison of systemic methotrexate administration and laparoscopic salpingostomy. Am J Obstet Gynecol 1999;181:945–51.
10. el-Lamie IK, Shehata NA, Kamel HA. Intramuscular methotrexate for tubal pregnancy. J Reprod Med 2002;47:144–50.
11. Ichinoe K, Wake N, Shinkai N, Shiina Y, Miyazaki Y, Tanaka T. Nonsurgical therapy to preserve oviduct function in patients with tubal pregnancies. Am J Obstet Gynecol 1987;156: 484–7.
12. Stovall TG, Ling FW, Buster JE. Outpatient chemotherapy of unruptured ectopic pregnancy. Fertil Steril 1989;51:435–8.
13. Elito J Jr., Reichmann AP, Uchiyama MN, Camano L. Predictive score for the systemic treatment of unruptured ectopic pregnancy with a single dose of methotrexate. Int J Gynaecol Obstet 1999;67:75–9.
14. Kucera E, Schindl M, Klem I, Sam C, Hanzal E, Kolbl H, et al. Could we treat more unruptured ectopic pregnancies with intramuscular methotrexate? Gynecol Obstet Invest 2000;49: 6–11.
15. Barnhart KT, Gosman G, Ashby R, Sammel M. The medical management of ectopic pregnancy: a meta-analysis comparing "single dose" and "multidose" regimens. Obstet Gynecol 2003;101:778–84.
16. Erdem M, Erdem A, Arslan M, Oc A, Biberoglu K, Gursoy R. Single-dose methotrexate for the treatment of unruptured ectopic pregnancy. Arch Gynecol Obstet 2004;270:201–4.
17. Bayram M, Ozogul C, Dursun A, Ercan ZS, Isik I, Dilekoz E. Light and electron microscope examination of the effects of methotrexate on the endosalpinx. Eur J Obstet Gynecol Reprod Biol 2005;120:96–103.
18. Cetin MT, Arisoy AH, Tap O, Kaya M, Urunsak I. Effects of methotrexate on the tubal morphology of rabbits: evaluation by electron microscopy. Gynecol Obstet Invest 2008;65:217–21.
19. Yang XJ, Wang HC, Chen YP, Zhao J, Zheng FY. Examination of the effects of methotrexate on histological and steroid receptor changes in the endosalpinx of the rat. Eur J Obstet Gynecol Reprod Biol 2009;146:193–9.
20. Bagshawe KD, Wilde CE. Infusion therapy for pelvic trophoblastic tumours. J Obstet Gynaecol Br Commonw 1964;71:565–70.
21. Tang A, Baartz D, Khoo SK. A medical management of interstitial ectopic pregnancy: a 5-year clinical study. Aust N Z J Obstet Gynaecol 2006;46:107–11.
22. Bayram M, Ozogul C, Ercan ZS, Dilekoz E, Soyer C, Bayram O. Examination of the rescue effects of folic acid on derangement of the tubo-ovarian ultrastructural architecture caused by methotrexate. Adv Ther 2006;23:772–7.
23. Paltieli Y, Eibschitz I, Ziskind G, Ohel G, Silbermann M, Weichselbaum A. High progesterone levels and ciliary dysfunction–a possible cause of ectopic pregnancy. J Assist Reprod Genet 2000;17:103–6.
24. Okada A, Ohta Y, Inoue S, Hiroi H, Muramatsu M, Iguchi T. Expression of estrogen, progesterone and androgen receptors in the oviduct of developing, cycling and pre-implantation rats. J Mol Endocrinol 2003;30:301–15.
25. Mobley AS, Mahendra G, Lucero MT. Evidence for multiple signaling pathways in single squid olfactory receptor neurons. J Comp Neurol 2007;501:231–42.
26. Spugnini EP, Arancia G, Porrello A, Colone M, Formisano G, Stringaro A, et al. Ultrastructural modifications of cell membranes induced by "electroporation" on melanoma xenografts. Microsc Res Tech 2007;70:1041–50.
27. Camacho-Arroyo I, Gonzalez-Aguero G, Gamboa-Dominguez A, Cerbon MA, Ondarza R. Progesterone receptor isoforms expression pattern in human chordomas. J Neurooncol 2000;49:1–7.
28. Darville T, O'Neill JM, Andrews CW Jr., Nagarajan UM, Stahl L, Ojcius DM. Toll-like receptor-2, but not Toll-like receptor-4, is essential for development of oviduct pathology in chlamydial genital tract infection. J Immunol 2003;171: 6187–97.
29. Vardi N, Parlakpinar H, Ozturk F, Ates B, Gul M, Cetin A, et al. Potent protective effect of apricot and beta-carotene on methotrexate-induced intestinal oxidative damage in rats. Food Chem Toxicol 2008;46:3015–22.
30. Sand PK, Stubblefield PA, Ory SJ. Methotrexate inhibition of normal trophoblasts in vitro. Am J Obstet Gynecol 1986;155:324–9.
31. Isaacs JD Jr., McGehee RP, Cowan BD. Life-threatening neutropenia following methotrexate treatment of ectopic pregnancy: a report of two cases. Obstet Gynecol 1996;88:694–6.
32. Weinblatt ME, Fraser P. Elevated mean corpuscular volume as a predictor of hematologic toxicity due to methotrexate therapy. Arthritis Rheum 1989;32: 1592–6.
33. Jeynes BJ, Altmann GG. Light and scanning electron microscopic observations of the effects of sublethal doses of methotrexate on the rat small intestine. Anat Rec 1978;191:1–17.
34. Harb JM, Werlin SL, Camitta BM, Oechler H, Kamin BA, Blank EL. Hepatic ultrastructure in leukemic children treated with methotrexate and 6-mercaptopurine. Am J Pediatr Hematol Oncol 1983;5:323–31.
35. Blumenfeld Z. How to preserve fertility in young women exposed to chemotherapy? The role of GnRH agonist cotreatment in addition to cryopreservation of embrya, oocytes, or ovaries. Oncologist 2007;12:1044–54.
36. McLaren JF, Burney RO, Milki AA, Westphal LM, Dahan MH, Lathi RB. Effect of methotrexate exposure on subsequent fertility in women undergoing controlled ovarian stimulation. Fertil Steril 2009;92:515–9.
37. Bleyer WA. Methotrexate: clinical pharmacology, current status and therapeutic guidelines. Cancer Treat Rev 1977;4:87–101.
38. Skarby TV, Anderson H, Heldrup J, Kanerva JA, Seidel H, Schmiegelow K. High leucovorin doses during high-dose methotrexate treatment may reduce the cure rate in childhood acute lymphoblastic leukemia. Leukemia 2006;20: 1955–62.
39. Sterba J, Valik D, Bajciova V, Kadlecova V, Gregorova V, Mendelova D. High-dose methotrexate and/or leucovorin rescue for the treatment of children with lymphoblastic malignancies: do we really know why, when and how? Neoplasma 2005;52:456–63.
40. Barnhart KT, Sammel MD, Gracia CR, Chittams J, Hummel AC, Shaunik A. Risk factors for ectopic pregnancy in women with symptomatic first-trimester pregnancies. Fertil Steril 2006;86:36–43.
41. Ajonuma LC, Ng EH, Chan LN, Chow PH, Kung LS, Cheung AN, et al. Ultrastructural characterization of whole hydrosalpinx from infertile Chinese women. Cell Biol Int 2005;29: 849–56.
42. Smith TT. The modulation of sperm function by the oviductal epithelium. Biol Reprod 1998;58: 1102–4.
43. Barratt CL, Cooke ID. Sperm transport in the human female reproductive tract–a dynamic interaction. Int J Androl 1991;14:394–411.
44. Kervancioglu ME, Djahanbakhch O, Aitken RJ. Epithelial cell coculture and the induction of sperm capacitation. Fertil Steril 1994;61: 1103–8.

45. Kervancioglu ME, Saridogan E, Aitken RJ, Djahanbakhch O. Importance of sperm-to-epithelial cell contact for the capacitation of human spermatozoa in fallopian tube epithelial cell cocultures. Fertil Steril 2000;74:780–4.
46. Verhulst G, Camus M, Bollen N, Van Steirteghem A, Devroey P. Analysis of the risk factors with regard to the occurrence of ectopic pregnancy after medically assisted procreation. Hum Reprod 1993;8:1284–7.
47. Tan J, Paria BC, Dey SK, Das SK. Differential uterine expression of estrogen and progesterone receptors correlates with uterine preparation for implantation and decidualization in the mouse. Endocrinology 1999;140:5310–21.
48. Sadan O, Ginath S, Rotmensch S, Boaz M, Golan A, Glezerman M. Role of steroid receptors in the pathogenesis of tubal pregnancy. J Reprod Med 2002;47:1031–4.
49. Shao R, Weijdegard B, Fernandez-Rodriguez J, Egecioglu E, Zhu C, Andersson N, et al. Ciliated epithelial-specific and regional-specific expression and regulation of the estrogen receptor-beta2 in the fallopian tubes of immature rats: a possible mechanism for estrogen-mediated transport process in vivo. Am J Physiol Endocrinol Metab 2007;293:E147–58.
50. David A, Garcia CR, Czernobilsky B. Human hydrosalpinx. Histologic study and chemical composition of fluid. Am J Obstet Gynecol 1969;105:400–11.
51. Howard LR, Pandjaitan N, Morelock T, Gil MI. Antioxidant capacity and phenolic content of spinach as affected by genetics and growing season. J Agric Food Chem 2002;50:5891–6.
52. Naik SR, Panda VS. Antioxidant and hepatoprotective effects of Ginkgo biloba phytosomes in carbon tetrachloride-induced liver injury in rodents. Liver Int 2007;27:393–9.
53. Yuncu M, Eralp A, Koruk M, Sari I, Bagci C, Inaloz S. Effect of vitamin A against methotrexate-induced damage to the small intestine in rats. Med Princ Pract 2004;13:346–52.